



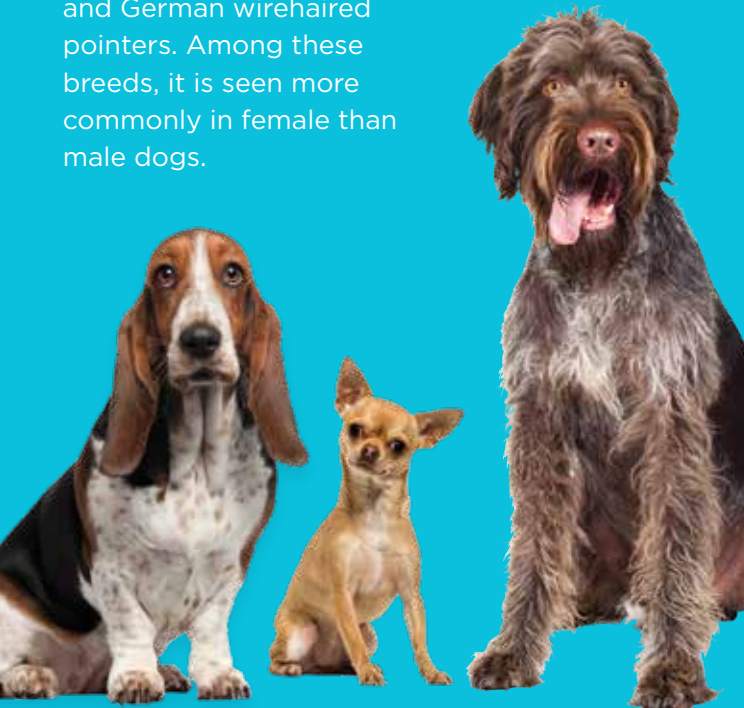ARE THERE OTHER CAUSES OF CORNEAL CLOUDINESS?

Most cases of diffuse cornea cloudiness occur due to loss or damage of the endothelial cells. In most of these cases, the condition is due to a genetic abnormality in these cells or so-called “dystrophy” or due to an age-related decline in these cells or “degeneration.” CED can also occur secondary to trauma (surgical and non-surgical), glaucoma, diabetes mellitus, uveitis/endotheliitis (inflammation of the eye and endothelial cells) and keratomalacia (enzymatic breakdown of the cornea).



WHAT BREEDS ARE PREDISPOSED TO THIS CONDITION?

While any breed of dog can develop this condition in their later years of life, breeds that are particularly predisposed to CED include the Boston terrier, Dachshund, Chihuahua, Basset hound, German shorthaired and German wirehaired pointers. Among these breeds, it is seen more commonly in female than male dogs.



ANIMAL VISION CENTER of VIRGINIA

521 Old Great Neck Road, Suite 2
Virginia Beach, VA 23454

(757) 749-4838

Dr. Heather Brookshire, DVM, DACVO

Visit us online at AnimalVisionCenterVA.com

 facebook.com/AVCVA

 instagram.com/AVCVA_STAFF

HOURS OF OPERATION

Monday, Wednesday, Friday 9:00 a.m. - 5:00 p.m.

Tuesday, Thursday 9:00 a.m. - 6:30 p.m.

One Saturday a Month 11:00 a.m. - 2:00 p.m.

SUFFOLK CLINIC at THE COVE Friday 9:00 a.m. - 12 p.m.
6550 Hampton Roads Parkway, Suffolk, VA 23435

SERVICES WE OFFER

Complete Exam & Diagnosis

Medical Therapy

Surgical Therapy

Orthopedic Foundation for Animals (OFA) Eye Exams & Registration

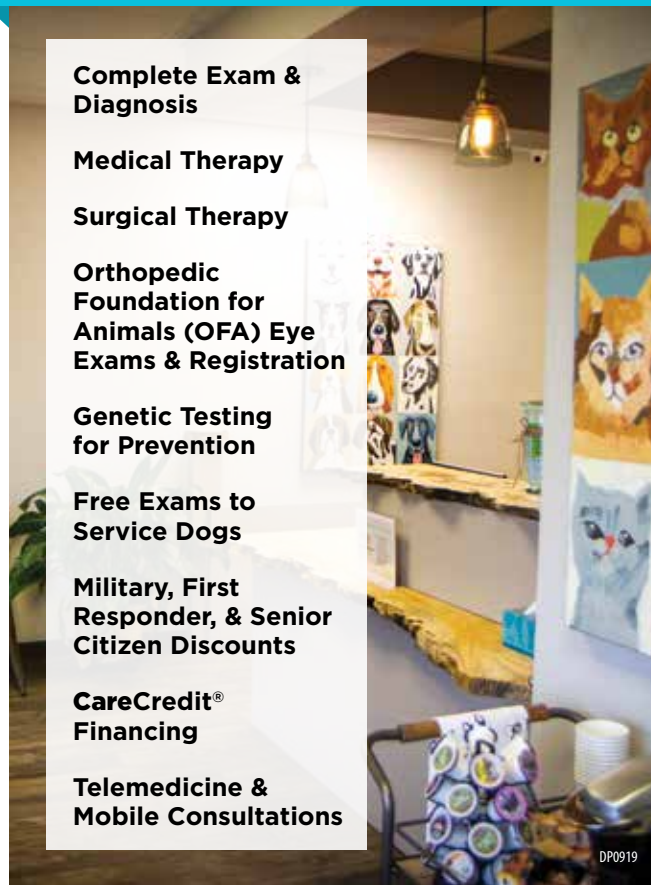Genetic Testing for Prevention

Free Exams to Service Dogs

Military, First Responder, & Senior Citizen Discounts

CareCredit® Financing

Telemedicine & Mobile Consultations



CORNEAL ENDOTHELIAL DEGENERATION



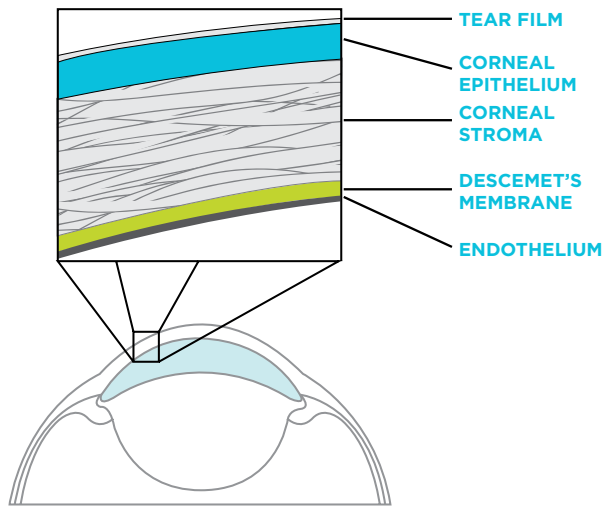
 **ANIMAL VISION CENTER of VIRGINIA**

Providing quality ophthalmic care for animals of all shapes and sizes so they can see a better life



CORNEAL ANATOMY

The cornea is the major refractive surface of the eye, and problems therein may lead to decreased vision. The corneal epithelial and endothelial layers function in a “sandwich capacity” on either side of the corneal stroma, keeping fluid out of this central layer. Loss of the epithelium/outer layer can increase the water content and swelling of the cornea by 200%, whereas loss of the endothelium/inner layer can cause the cornea to swell by 500%. This demonstrates the critical function of the endothelial cells to maintain the cornea’s clarity.



WHAT IS CORNEAL ENDOTHELIAL DEGENERATION?

Corneal endothelial degeneration (CED) is an age-related process by which the single layer of cells on the inside of the cornea (endothelial cells) prematurely decline in number and function. These cells contain tiny “pumps” that normally regulate the amount of fluid within the cornea throughout life and help to ensure it remains transparent and free of fluid accumulation (corneal edema). When the cell number declines to a critical density, fluid begins to leak into the cornea causing it to become water-logged, swollen and opaque—thus limiting vision.



HOW IS IT TREATED?

There are three general means to treat Corneal Endothelial Degeneration:

PALLIATIVE MEDICAL THERAPY

Palliative therapy attempts to slow the progression of the disease, while managing the painful secondary complications of the condition. Topical medical therapy, such as hypertonic saline ointment and non-steroidal anti-inflammatory drugs (NSAIDS), help to minimize the accumulation of fluid in the top layer of the cornea and prevent fluid blisters or “bullae” from forming. In more advanced states of CED, medical therapy is unable to control the formation of the fluid blisters, and these can rupture to produce painful, slow-healing corneal erosions and ulcers. When non-healing ulcers develop, we commonly need to assist in the healing process with procedures such as diamond burr debridement and/or grid keratotomy, corneal cross-linking (CXL), or thermokeratoplasty.

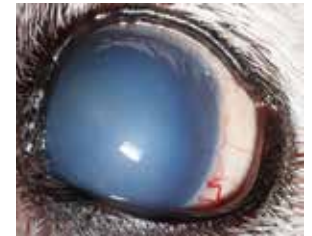PALLIATIVE SURGICAL THERAPY

Surgical therapy is the only real means to make a difference in the underlying pathophysiology of this condition. A wide array of surgical procedures may slow or reverse the changes seen with CED. These include Gundersen flap placement (keratectomy and conjunctival graft), corneal cross-linking (CXL), superficial keratectomy with CXL, penetrating keratoplasty (PK) and Descemet’s stripping endothelial keratoplasty (DSEK). A Gundersen flap can be helpful early on (prior to the development of diffuse corneal edema) to help halt the clinical progression of disease and to eliminate the potential for recurrent corneal erosions in the region of graft placement. It can, however, result in a relatively opaque graft on the surface of eye. The cross-linking procedures have been shown to benefit by eliminating chronic non-healing erosions; however these procedures have not shown lasting results in regard to clearing of the cornea.

CORNEAL TRANSPLANT PROCEDURES

From a biologic standpoint, the only way to “cure” CED is to replace the diseased inner layer of the cornea with a new healthy layer of cells. This can only be accomplished with a corneal transplant procedure. Historically, this has been done with a full-thickness corneal transplant, or “penetrating keratoplasty.” This procedure has worked very well for some patients, but also carries a high risk of secondary complications such as graft rejection (failure of improvement in transparency), wound dehiscence (break down of the incision) and glaucoma (high pressure in the eye).

A newer procedure called **Descemet’s stripping endothelial keratoplasty (DSEK)** has significantly improved outcomes in canine corneal transplantation.



The goal of DSEK is to take a completely opaque CED compromised cornea, such as the one shown above, and to selectively transplant only the diseased endothelium, ultimately resulting in fewer post-operative complications, lower rates of rejection, and increased visual outcomes.

ANIMAL VISION CENTER OF VIRGINIA is one of only a small handful of practices in the world that is currently performing DSEK to restore sight in dogs.

